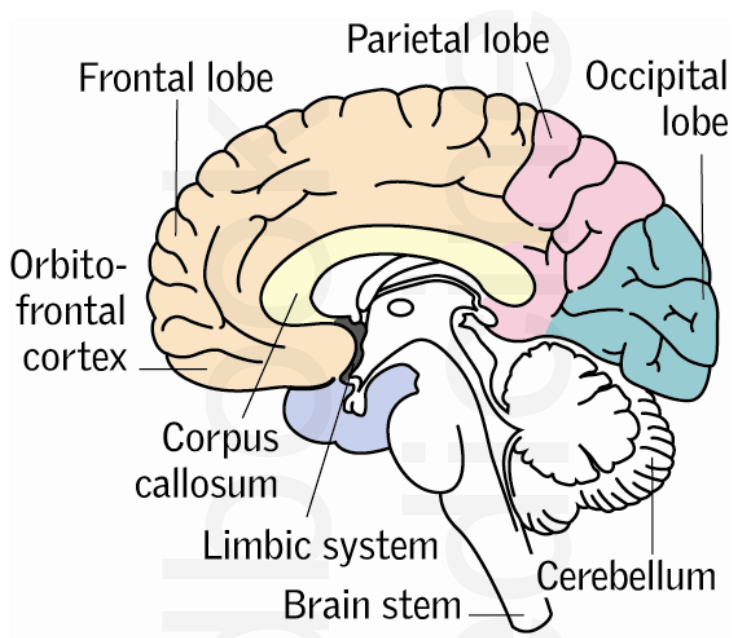
Parietal lobe
Frontal lobe
Occipital lobe
Orbito-frontal cortex
Corpus callosum
Limbic system
Cerebellum
Brain stem

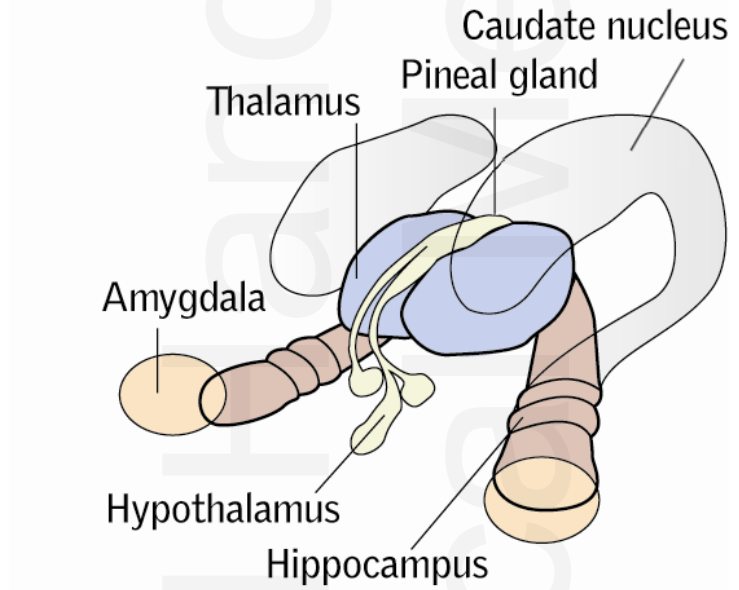
Caudate nucleus
Pineal gland
Thalamus
Amygdala
Hypothalamus
Hippocampus

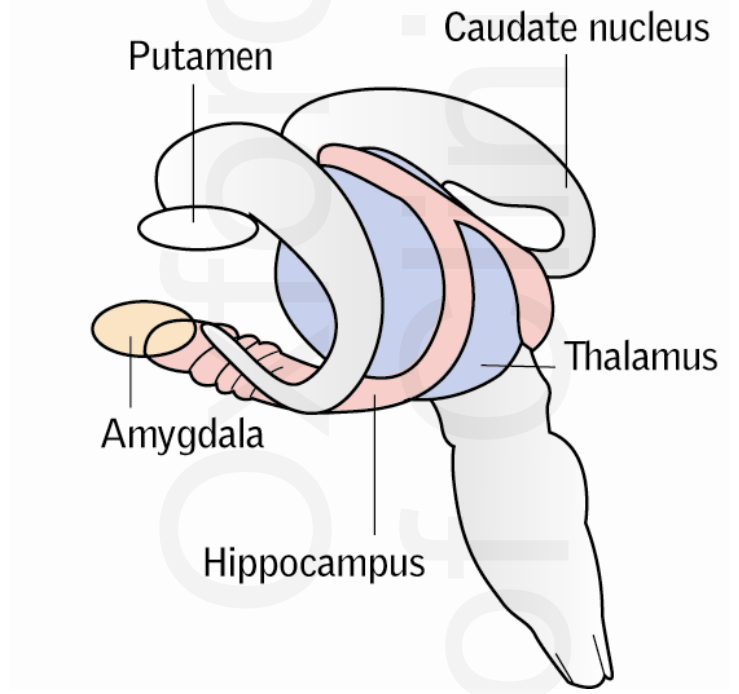
Caudate nucleus
Putamen
Thalamus
Amygdala
Hippocampus